

# Surgical Management of a Severe Case of Gingival Fibromatosis

Munagala Karthik Krishna, Lumbini Pathivada, Gopinath Vivekanandan, Sunaina Shetty

<sup>1</sup>Department of Periodontology, Teerthanker Mahaveer Dental College and Research Centre, Moradabad, India, <sup>2</sup>Department of Pedodontics and Preventive Dentistry, Teerthanker Mahaveer Dental College and Research Centre, Moradabad, India, <sup>3</sup>Department of Periodontology, Chattisgarh Dental College and Research Institute, Rajnandgaon, India.

## Abstract

Gingival fibromatosis (GF) is a fibrous overgrowth of gingiva that maybe idiopathic or may have an inheritance pattern wherein it is known as hereditary gingival fibromatosis (HGF). This case report describes a 16-year old female patient who presented generalized extensive gingival overgrowth, involving the maxillary and mandibular arches. Diagnosis of GF was substantiated by the patient's clinical features and histopathological examination. Excision of the gingival tissue was done by gingivectomy with manual instrumentation and electrosurgery. The postoperative course was uneventful and the patient's aesthetic concerns were addressed. Thus, in severe cases of GF, the use of multiple modalities of surgery is warranted to achieve favorable esthetic and functional results.

*Key Words: Gingival fibromatosis, Gingival enlargement, Electrosurgery, Gingivectomy*

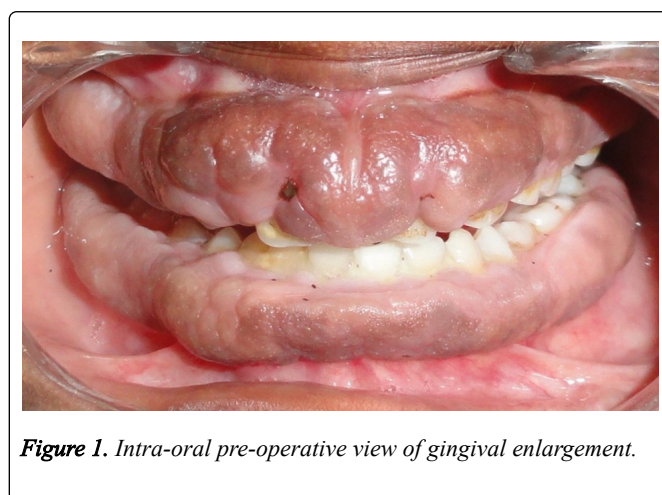
## Introduction

Gingival fibromatosis (GF) is a genetically heterogeneous disorder, clinically characterized by a firm, painless enlargement of the gingiva. The hyperplastic tissue is of normal colour and the degree of swelling varies from the mild to the grotesque. The enlargement usually begins with the eruption of the permanent dentition and is rarely present at birth. It may manifest in syndromic conditions in association with mental retardation, epilepsy, progressive sensorineural hearing loss, and abnormalities of the toes and fingers, but hypertrichosis is the ancillary abnormality most commonly seen [1,2]. This case report describes a case of severe gingival enlargement along with radiographic features, histological appearance and surgical management of the condition.

## Case Report

A 16-year old female patient presented with the chief complaint of swollen gums, facial deformity and difficulty in eating properly. She recalled having swollen gums since she was around 8 years old. She also complained of inability to close her mouth completely and difficulty in chewing hard foods due to which she was on a semi-solid/liquid diet since 6 years. Although patient reported similar enlargement in her mother, this could not be confirmed as the latter was not available for examination.

Clinical examination showed hypertrichosis, characterized by bushy eyebrows and growth of dark brown hair present on both the upper and lower limbs. Intraorally, the gingiva showed diffuse and generalized enlargement in both buccal and lingual aspects. Enlargement was severe in the maxillary anterior region with only incisal edges being visible. The gingival was firm, almost leathery, on palpation with normal colour (*Figure 1*). Plaque and calculus were minimal but mild halitosis was present. Radiological examination showed initial bone loss with flattening of the crestal bone.



*Figure 1. Intra-oral pre-operative view of gingival enlargement.*

A provisional diagnosis of fibromatous gingival enlargement with secondary inflammation was considered. Patient was subjected to ultrasonic scaling, given oral hygiene instructions, prescribed a 0.2% chlorhexidine mouthrinse to be used twice daily and recalled after 1 week for incisional biopsy.

## Histopathological examination

The biopsy specimen showed parakeratinized stratified squamous epithelium with loss of rete pegs in few areas and an underlying connective tissue stroma with dense interlacing fiber bundles was seen. Several inflammatory cells, predominantly lymphocytes and a few macrophages were observed. Few endothelial lined blood vessels were also present within the stroma (*Figure 2*). All these features were suggestive of HGF.

Surgical therapy for the patient was planned on the third visit. Required premedication and local anesthesia was administered to patient. Internal bevel gingivectomy was employed to remove a significant bulk of the fibrous tissue (*Figure 3*).

## Discussion

HGF is known by several terms such as gingivomatosis, elephantiasis, idiopathic fibromatosis, hereditary gingival hyperplasia, congenital familial fibromatosis and idiopathic gingival fibromatosis [3]. Although the features in the proband were suggestive of HGF, an inheritance pattern could not be confirmed due to unavailability of family members for examination.

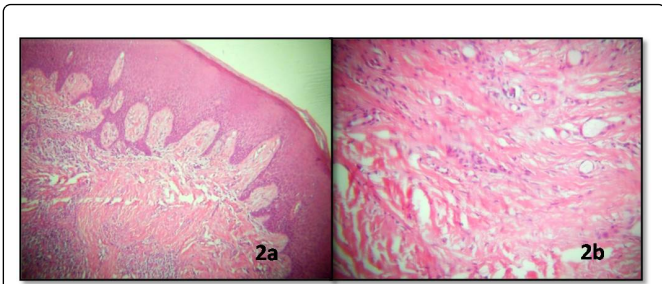
The precise mechanism of enlargement is unknown but is believed to originate from the hyperactivity of gingival fibroblasts and may involve disproportionate buildup of extracellular proteins, the most prominent being type I collagen [4]. The presence of teeth may be necessary for the commencement of the growth process. Severe GF, as in the present case, are associated with partially erupted or submerged dentition and increased vertical occlusal dimension and incompetent lips, features that cumulatively contribute to a negative effect on facial esthetics [5].

Few syndromic associations of GF associated with hypertrichosis have been reported in the literature such as Ramon syndrome, Zimmerman-Laband syndrome, Cross syndrome and Rutherford syndrome although the mild hypertrichosis in the reported case did not justify her categorization under any of these conditions [6,7].

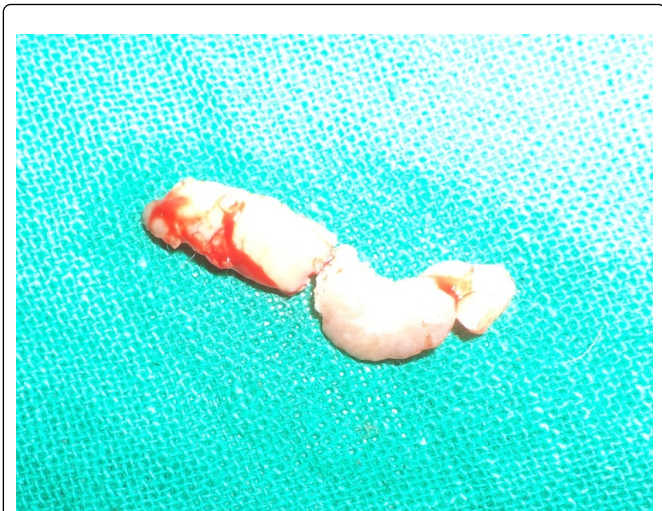
HGF is believed to be inherited by a dominant mode of transmission by mutation of the gene, son of sevenless-1 (SOS1), although other types of mutations maybe involved because of the heterogenous presentation of the condition [4]. In fact, recent evidence suggests that HGF can be included in RASopathies or RAS/mitogen-activated protein kinase (MAPK) syndromes, a group of conditions that overlap phenotypically and are caused by germline mutations encoding components of the RAS/MAPK signaling pathway [8].

Although histopathological examination showed dense interlacing fiber bundles, the specific type could not be evaluated. Studies on ultrastructural evaluation of the connective tissue in HGF with transmission electron microscopy revealed significant presence of oxytalan fibers. Also, the diameters of collagen fibrils and dimensions of interfibrillar spaces were more variable as compared to normal gingiva. The fibrils showed signs of their typically repeating banding pattern with some end loops and, in some areas, fibrils were tortuous with lack of the alignment between them [9].

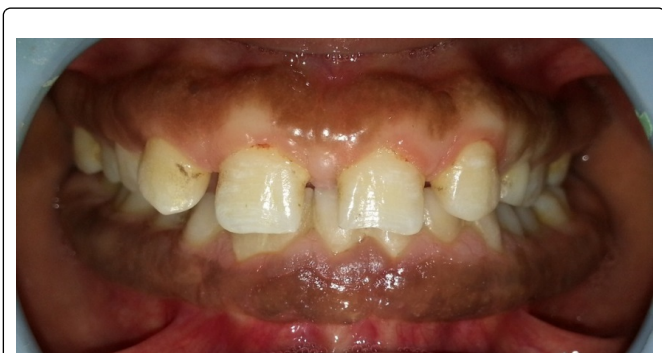The treatment of GF varies from simple oral hygiene measures and scaling for mild cases to additional surgical procedures in more severe cases. The excessive growth of gingivae and the associated disturbances in speech and esthetics warranted a surgical approach in this case. Both conventional as well as electrosurgical procedures were employed to attain an acceptable esthetic result. Several case reports have reported minimal recurrence for periods from 6 months to 2 years after surgical excision [10,11]. In the present case, there was minimal recurrence of the gingival enlargement, despite her poor oral hygiene.



**Figure 2.** 2a: stained section of the excised tissue showing stratified squamous epithelium with and an underlying dense connective tissue stroma; 2b: higher magnification of the same section showing dense interlacing fiber bundles.



**Figure 3.** A portion of the excised fibromatous tissue.



**Figure 4.** 15-months post-operative view

A physiologic gingival contour was obtained using electrocautery with loop electrode under coagulation setting. Due to the extensive nature of the enlargement, surgical treatment was done in two visits. Patient was prescribed antibiotics and analgesics for one week during the course of therapy and recalled after one week. The postsurgical healing was uneventful and subsequently, patient was able to report for recall visits for 15 months post-operatively. The gingival enlargement showed mild recurrence, probably due her inability to maintain proper oral hygiene (Figure 4).

## Conclusion

Although similar in clinical presentation, the etiology and pathogenesis of GF are distinct from other types of gingival enlargements, requiring a thorough differential diagnosis. The influence of this condition on esthetics and masticatory function often demands surgical intervention, although recurrence cannot be predicted.

## References

1. Anderson J, Cunliffe WJ, Roberts DF, Close H. Hereditary Gingival Fibromatosis. *British Medical Journal*. 1969; **3**: 218-219.
2. Bittencourt LP, Campos W, Moliterno LFM, Ribeiro DPB, Sampaio RK. Hereditary Gingival Fibromatosis: Review of the Literature and a Case Report. *Quintessence Int*. 2000; **31**: 415-418.
3. Newman MG, Takei HH, Carranza FA. *Carranza's Clinical Periodontology*. W.B. Saunders Company, 2002. Print.
4. Gawron K, Łazarz-Bartyzel K, Potempa J, Chomyszyn-Gajewska M. Gingival fibromatosis: clinical, molecular and therapeutic issues. *Orphanet Journal of Rare Diseases*. 2016; **11**: 9.
5. Michaud PL, Patel A. Hereditary gingival fibromatosis with extreme ridge thickness and insufficient interarch distance: A clinical report of surgical and prosthetic management. *Journal of Prosthetic Dentistry*. 2016; **116**: 15-20.
6. De Angelo S, Murphy J, Claman L, Kalmar J, Leblebicioglu B. Hereditary Gingival Fibromatosis-A Review. *Compendium*. 2007; **28**: 138-144.
7. Alexander, Peter S, Nampoothiri S, Rao L, Nambiar A, et al. Ramon's Syndrome: A Rare Entity. *World Journal of Dentistry*. 2010; **1**: 199-204.
8. Aoki Y, Niihori T, Inoue S, Matsubara Y. Recent advances in RASopathies. *Journal of Human Genetics*. 2016; **61**: 33-39.
9. Pego SP, Coletta RD, Mendes DC, de Faria PR, Melo-Filho MR, et al. Hereditary gingival fibromatosis: clinical and ultrastructural features of a new family. *Medicina Oral, Patologia Oral Y Cirugia Bucal*. 2015; **20**: e150-155.
10. Zhou M, Xu L, Meng HX. Diagnosis and treatment of a hereditary gingival fibromatosis case. *The Chinese Journal Of Dental Research*. 2011; **14**: 155-158.
11. Pol DG, Lobo TM, Pol SD. Idiopathic gingival fibromatosis with asymmetrical presentation and electrosurgical management. *Journal of Indian Society of Periodontology*. 2016; **20**: 98-102.